

## A Case of a Late and Atypical Knee Prosthetic Infection by No-Biofilm Producer *Pasteurella multocida* Strain Identified by Pyrosequencing

CARLO L. ROMANÒ<sup>1</sup>, ELENA DE VECCHI<sup>2</sup>, CHRISTIAN VASSENA<sup>2</sup>, GIOVANNI MANZI<sup>1</sup>  
and LORENZO DRAGO<sup>2,3\*</sup>

<sup>1</sup>C.R.I.O. Unit IRCCS Galeazzi Orthopaedic Institute Milan, Italy

<sup>2</sup>Laboratory of Clinical Chemistry and Microbiology IRCCS Galeazzi Orthopaedic Institute Milan, Italy

<sup>3</sup>Department of Biomedical Science for Health, University of Milan, Milan, Italy

Submitted 29 January 2012, revised 30 June 2013, accepted 18 October 2013

### Abstract

Prosthetic joint infections due to *Pasteurella multocida* are rarely but increasingly reported but no data on production of biofilm are available. We report the case of a woman with a late, haematogenous peri-prosthetic infection of cemented total knee arthroplasty caused by a strain of *P. multocida* identified by pyrosequencing and unable to produce biofilm. Comparison of clinical and laboratory findings with those reported in other patients evidenced differences mainly in the period of symptoms' onset and in the behaviour of some inflammatory markers.

**Key words:** *Pasteurella multocida*, bacterial biofilm, prosthetic joint infections

Prosthetic joint infections (PJIs) are widely recognized as an important cause of failure in total knee arthroplasty (TKA) and are usually classified as early, delayed and late, according to Cobo and Del Pozo (2011); Romanò *et al.* (2011). Late infections account for about one-third of reported TKA infections and are generally caused by low-grade pathogens (Insall *et al.*, 1983). Production of biofilm is often associated with PJIs, feature that makes these infections of major concern for clinicians (Cobo and Del Pozo, 2011). *Pasteurella multocida* is a Gram-negative bacillus, belonging to the normal nasopharyngeal and gastrointestinal flora of cats and other animals and has been occasionally reported as cause of delayed or late PJIs; generally, an animal bite or scratch can be identified in the patient's recent history and haematogenous spreading of bacteria from this distant source is thought to be the pathogenetic starter of implant colonization and onset of the infection (Mahapatra and Mulcahy, 2002). At our best knowledge rather few data are available on ability to form biofilm by *P. multocida* and they mainly concern isolates from animal infections (Olson *et al.*, 2002). Here we report a case of acute, late, haematogenous infection of a cemented knee prosthesis, caused by a strain of *P. multocida*, which was characterized for in vitro biofilm production.

A 82 year-old woman was referred to our department in May 2010 because of an acute onset of a PJI of her left total knee cemented prosthesis, implanted four years before (Fig. 1A). In July 2000 a total knee replacement had been implanted to the patient for severe knee rheumatoid arthritis; early revision of the wound was required, due to post-surgical bleeding. Asymptomatic for the following years, she underwent femoral component revision for "aseptic loosening". In May 2010 she presented to our observation with a swelling, painful and warm knee with functional limitation and a draining fistula in the anterior aspect of the mid-leg. Clinical history revealed cat scratches over the homolateral foot and ankle five months before, followed by local erythema, that resolved after a short antibiotic course administered by the general practitioner (amoxicillin-clavulanic acid 1 g twice a day for ten days). At admission to our hospital, C-reactive protein (CRP) was 7.67 mg/dL, Erythrocyte Sedimentation Rate (ESR) 120 mm/hr, white blood cells count  $8.3 \times 10^3/\mu\text{L}$  and haemoglobin level 9.7 g/dL. Plain x-ray showed no sign of prosthetic loosening (Fig. 1B). Cultures from the fistula were negative. In June 2010 surgical debridement with change of the mobile parts of the prosthesis (polyethylene tibial tray) and intra-operative cultural examination was performed both at the joint and at

\* Corresponding author: L. Drago, Lab of Clinical Chemistry and Microbiology IRCCS Galeazzi Orthopaedic Institute, Via R. Galeazzi 4, 20161 Milan, Italy; phone: (0039) 02-66214839; fax: (0039)02-66214774; e-mail: [lorenzo.drago@unimi.it](mailto:lorenzo.drago@unimi.it)

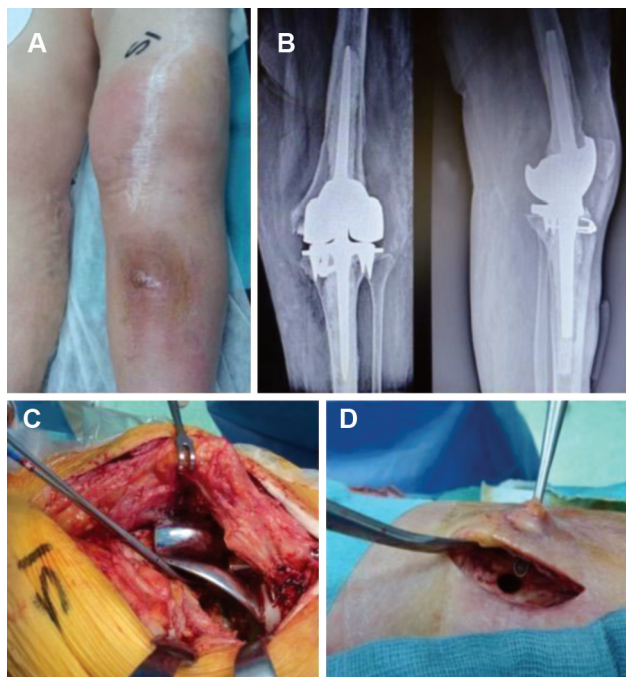


Fig. 1. Panel A: Clinical presentation in May 2010 of the acute, late, haematogenous infection of the left cemented knee joint prosthesis; Panel B: Antero-posterior and lateral X-ray views at the time of infection occurrence; Panel C: Intra-operative evidence of peri-prosthetic infection and osteolysis at the joint level; Panel D: Mid-shaft tibial bone fistula in communication with the skin.

the tip of the tibial prosthetic stem, where there was the draining fistula (Fig. 1C and 1D). All six intra-operative samples yielded *P. multocida*, identified by biochemical methods (API NH, Biomerieux Nany l'Etoile, France) and subsequently confirmed by Pyrosequencing (PSQ96RA, Diatech, Jesi, Italy) of three regions of the 16S ribosomal gene, as previously reported by Jonasson *et al.* (2002). The obtained sequences were compared with bacterial 16S rDNA sequences available at NCBI using the BLAST advanced options tools including taxonomy and lineage reports (available at <http://blast.ncbi.nlm.nih.gov/Blast.cgi>). Isolated *P. multocida* proved susceptible to  $\beta$ -lactams, fluoroquinolones and tetracycline. Histological examination of the joint capsule and peri-prosthetic tissues revealed a chronic synovitis with more than 10 leukocytes per field, compatible with infection. Preoperatively and during the postoperative course the levels of procalcitonin (PCT) and interleukin 6 (IL-6) were determined by a quantitative electrochemiluminescence assay run on an automated immune analyzer (Elecys BRAHMS PCT, Hennigsdorf/Berlin, Germany) and by an ELISA sandwich assay (Quantikine<sup>®</sup>, R&D Systems, Minneapolis, MN, USA), respectively. PCT level at admission and in the early postoperative hours was between 0.46 ng/mL and 0.52 ng/mL, and fell below the upper reference limit (0.5 ng/mL) in the following days to reach a concentrations of 0.31 ng/mL 5 days after sur-

gery. Pre- and post-operative IL-6 concentrations were 12.37 and 14.42 pg/ml respectively and 6.89 pg/ml at 5 days after surgery. Screening of biofilm production was investigated by an *in vitro* spectrophotometric method as previously described by Christensen *et al.*, 1985. The amount of biofilm was quantified by reading optical density (O.D.) at a wavelength of 595 nm. The assay was performed in duplicate and repeated for three times. Amount of biofilm produced by the isolate was compared with that produced by another strain of *P. multocida* from our collection and the ATCC strain 6529, which had been previously characterized for their production of biofilm and used as positive controls.

Spectrophotometric analysis evidenced no production of biofilm by the human isolate differently by the positive controls (O.D. 0.256 vs 1.610 and 1.242 respectively). In order to confirm the spectrophotometric assay, we have tested through confocal laser scanning microscopy (CLSM), the ability of our strain to produce biofilm on prosthetic material. Briefly, sandblasted titanium disks with 20 mm diameter and 6 mm thick were used as a substrate for the biofilm formation while, FilmTracer<sup>™</sup> LIVE/DEAD<sup>®</sup> Biofilm Viability Kit (Invitrogen, Ltd. Paisley, UK) is the staining used for biofilm. We used a confocal laser scanning microscope Leica TCS SP5 CLSM, opting for a three-dimensional *z-stack* acquisition (in a solid field described by the axes *xyz*) of five different portions for each disk. Sections were acquired in succession along the *z*-axis for a total of 150  $\mu$ m thickness. Acquired images during the experimental session were processed through a segmentation algorithm (Volocity; Perkin Elmer, Waltham, MA) capable of separating the signal from the background and the sample, in order to obtain a proportionality between the number of bacteria and the fluorescent signal. This analysis confirms the previous screening test because, even in this case, it demonstrates how the clinical strain isolated not produce biofilm (Fig. 2B) compared to positive controls (Fig. 2A). The patient was

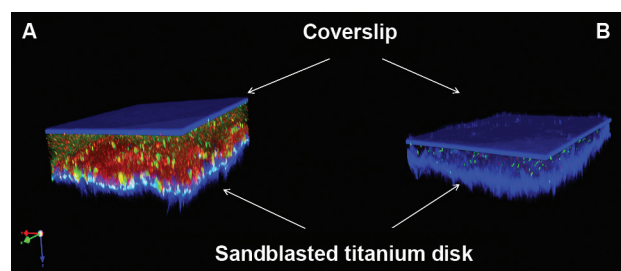


Fig. 2. 3D reconstruction of *P. multocida* biofilms by CLSM. Biofilms were stained with FilmTracer<sup>™</sup> LIVE/DEAD<sup>®</sup> Biofilm viability kit: SYTO9 (green) represents the viable cells; Propidium iodide (red) represents the dead cells. Panel A: *P. multocida* ATCC strain 6529 (Positive control); Panel B: Clinical strain isolate from patient.

treated with a combination of amoxicillin-clavulanic acid 1 g three times a day for 34 days and ciprofloxacin 750 mg per day for 42 days, according to bacterial antibiotic susceptibility pattern. One week after surgery the patient was transferred to the rehabilitation unit of our institute. She remained there for 15 days. When she left the hospital, her leukocyte count was  $4.5 \times 10^3/\mu\text{L}$ , haemoglobin level was 8.9 g/dL, CRP 4.3 mg/dL, procalcitonin <0.5 ng/mL and IL-6 was 4.35 pg/mL. Eighteen months after surgery, there are no clinical signs of infection recurrence, CRP and ESR had returned to baseline levels.

Only few cases of PJIs, caused by *P. multocida*, have been described over the last two decades (Antuna *et al.*, 1997). Known risk factors for *P. multocida* infections include age, diabetes, rheumatoid arthritis, obesity, immunosuppression, previous surgical interventions and renal insufficiency (Heym *et al.*, 2006). A part from rheumatoid arthritis and age, no other risk factors known to be associated to *P. multocida* infection were recognized, and clinical history did not evidence other predisposing conditions.

As in our case, in all the previously reported ones, the infection occurred late after joint prosthesis implant and a distal source was identified. However, differently from what observed in other cases, symptoms arose rather far from the cat bite (5 months vs a maximum of 2 months) and did not include fever. The lack of fever as well as the moderate increase in CRP and leukocyte count in respect to the other reported cases (7.67 mg/dL vs 27.7 mg/dL and  $8.3 \times 10^3/\mu\text{L}$  vs  $14.6 \times 10^3/\mu\text{L}$ ) could suggest a clinical picture of masked effect of the immunocompromised state of the host as affirmed by Metha and Mackie (2004) but, in this case, we did not find parameters confirming an altered immune status of the patient. For this reason, we hypothesized that the moderate elevation of inflammatory parameters could be due to the longer time elapsed from the cat bite in respect to what has been reported by other authors (Heym *et al.*, 2006; Metha and Mackie, 2004). Maradona *et al.* (1997) advise that antibiotic prophylaxis would be prudent in patients who have suffered a pet bite or scratch and have a prosthetic joint. One- or two-stage revision surgery is recommended in cases of septic implant loosening. In acute, late haematogenous infection, surgical debridement with prosthesis retention may be attempted as a salvage procedure, with a success rate < 80% (Heym *et al.*, 2006). In particular, according to Heym, surgical debridement and antibiotic therapy, without removal of an infected TKA, are indicated when the infection is acute, the responsible microorganism has been isolated, the organism is susceptible to oral antibiotics, antibiotics could be tolerated without serious toxicity, and the prosthesis was not loose (Heym *et al.*, 2006). Old age and the presence

of a well fixed, long-stemmed, cemented revision joint prosthesis, whose removal is particularly challenging and associated with severe bone loss, were the other factors that prompted us to try a salvage procedure of the implant in this particular case.

The role of biofilm in PJIs is well known and its presence has been related to chronic infections and to difficulties in their eradication. Ability of *P. multocida* to produce biofilm has been rarely evaluated. Available studies indicate *in vitro* production of biofilm by strains of animal origin (Olson *et al.*, 2002). Nonetheless, it may be hypothesized that the ability to produce biofilm might be different *in vitro* and *in vivo*, where host factors may favor its formation. However, comparison with the positive control strains clearly indicated the absence of biofilm production by the tested isolate.

The role of PCT in diagnosis of PJIs is matter of debate, since no clear evidences of its usefulness have been provided. In a recent study, PCT was found to be of no value in differentiating septic loosening (Drago *et al.*, 2011) and this patient confirmed these results. In contrast, IL-6 levels remained higher than the normal range in the preoperative and postoperative phases, confirming its reliability as useful marker of prosthetic infection.

In the light of our result, the observed differences compared to other cases, highlight the importance of measuring alternative inflammatory parameters in diagnosing prosthetic infection.

Although obtained in an isolated case and at a relatively short follow-up, considering biofilm production as a potent virulence factor for bacteria that colonize implanted biomaterials, one may speculate if implant-related infections, caused by no-biofilm producing bacteria, may be treated with systemic antibiotic and prosthesis retention with a better prognosis than implant-related infection associated with biofilm producing bacteria.

## Literature

- Antuna S.A., J.G. Mendez, J.L. Castellanos and J.P. Jimenez. 1997. Late infection after total knee arthroplasty caused by *Pasteurella multocida*. *Acta Orthop. Belg.* 63: 310–312.
- Christensen G.D., W.A. Simpson, J.J. Younger, L.M. Baddour, F.F. Barrett, D.M. Melton and E.H. Beachey. 1985. Adherence of coagulase-negative staphylococci to plastic tissue culture plates: a quantitative model for the adherence of staphylococci to medical devices. *J. Clin. Microbiol.* 22: 996–1006.
- Cobo J. and J.L. Del Pozo. 2011. Prosthetic joint infection: diagnosis and management. *Expert Rev. Anti Infect. Ther.* 9: 787–802.
- Drago L., C. Vassena, E. Dozio, M.M. Corsi, E. De Vecchi, R. Mattina and C.L. Romano. 2011. Procalcitonin, C-reactive protein, interleukin-6, and soluble intercellular adhesion molecule-1 as markers of postoperative orthopaedic joint prosthesis infections. *Int. J. Immunopathol. Pharmacol.* 24: 433–40.



- Heym B., F. Jouve, M. Lemoal, A. Veil-Picard, A. Lortat-Jacob and M.H. Nicolas-Chanoine. 2006. *Pasteurella multocida* infection of a total knee arthroplasty after a "dog lick". *Knee Surg. Sports Traumatol. Arthrosc.* 14: 993–997.
- Insall J.N., F.M. Thompson and B.D. Brause. 1983. Two-stage reimplantation for the salvage of infected total knee arthroplasty. *J. Bone Joint Surg. Am.* 84–A: 490.
- Jonasson J., M. Olofsson and H.J. Monstein. 2002. Classification, identification and subtyping of bacteria based on pyrosequencing and signature matching of 16S rDNA fragments. *APMIS*. 110: 263–272.
- Mahapatra A.N. and D. Mulcahy. 2002. *Pasteurella multocida* osteomyelitis following a dog bite. *Ir. J. Med. Sci.* 171: 56.
- Maradona J.A., V. Asensi, J.A. Carton, A. Rodriguez Guardado and J. Lizón Castellano. 1997. Prosthetic joint infection by *Pasteurella multocida*. *Eur. J. Clin. Microbiol. & Infect. Dis.* 16(8): 623–625.
- Mehta H. and I. Mackie. 2004. Prosthetic joint infection with *Pasteurella multocida* following cat scratch: a report of 2 cases. *J. Arthroplasty*. 19(4): 525–7.
- Olson M.E., H. Ceri, D.W. Morck, A.G. Buret and R.R. Read. 2002. Biofilm bacteria: formation and comparative susceptibility to antibiotics. *Can. J. Vet. Res.* 66(2): 86–92.
- Romanò C.L., N. Logoluso, F. Dell'Oro, A. Elia and L. Drago. 2011. Bone and joint infections in adults: a comprehensive classification proposal. *Eur. Orthop. Traumatol.* 1/6: 207–217.